

# Abdominal Effusion in a Bird

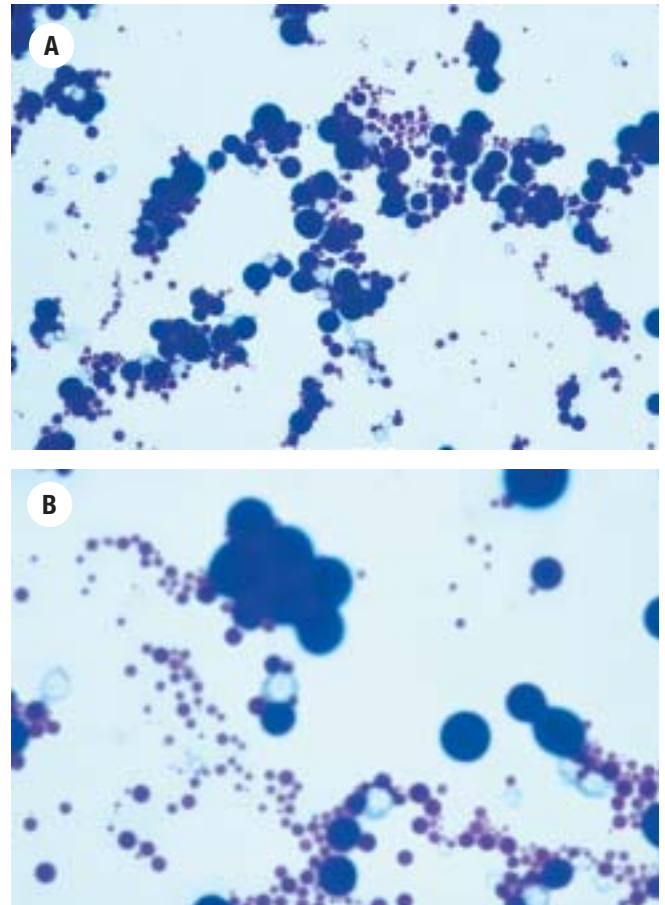
Kimberly J. Caruso, Rick L. Cowell, James H. Meinkoth, James K. Klaassen

**What Is Your  
Diagnosis?**

## Case Presentation

A 2-year-old female cockatiel was presented for abdominal swelling of 3 weeks duration. The bird appeared otherwise normal. On physical examination, the abdomen was distended, but no masses were palpable. Abdominocentesis was performed, and 0.5 mL of fluid was removed and submitted to Antech Diagnostics for fluid analysis and cytology. The fluid was light yellow and hazy and had a specific gravity of 1.042, a total protein concentration (by refractometry) of 7.4 g/dL, 250 WBC/ $\mu$ L and <10,000 RBC/ $\mu$ L. Direct smears, sediment smears, and cytocentrifuged preparations (Shandon Cytospin II, Shandon Lipshaw, Pittsburgh, Pa, USA; 66 rpm for 6 min) were made for cytologic evaluation (Figure 1).

*(Continued on next page)*



**Figure 1.** Cytocentrifuged preparation of abdominal fluid from a cockatiel. Wright-Giemsa, (A)  $\times 125$ , (B)  $\times 250$ .

From the Department of Veterinary Pathobiology, College of Veterinary Medicine, Oklahoma State University (Caruso, Cowell, Meinkoth), Stillwater, Okla, and Antech Diagnostics, Irvine, Calif (Klaassen). Corresponding author: Dr. Kimberly J. Caruso, Veterinary Medical Teaching Hospital, Clinical Pathology Laboratory, University of California, 1 Shields Ave, Davis, CA 95616 (kjaruso@vmth.ucdavis.edu).

### Cytologic Interpretation

Examination of the smears revealed numerous round dark blue amorphous globules thought to be protein globules, scattered amorphous crystals, and low numbers of macrophages (Figure 1). The protein globules were of various sizes, and staining intensity ranged from eosinophilic to basophilic. Occasionally, the protein globules touched, mimicking a budding yeast (Figure 1B). No neoplastic cells or infectious organisms were noted. The cytologic diagnosis was egg yolk peritonitis.

### Discussion

Egg yolk peritonitis, ie, the presence of yolk material in the coelomic cavity, is a common cause of abdominal distension in birds. Yolk material by itself induces a mild inflammatory response and may be reabsorbed by the peritoneum. Because yolk is an excellent growth medium for bacteria, peritonitis may result from secondary bacterial infection.<sup>1</sup> Localized to diffuse fibrinous peritonitis may result, and may lead to secondary ascites and organ inflammation or compromise in chronic cases.<sup>2</sup>

Clinical signs include sudden death, anorexia, weakness, depression, respiratory distress, and ascites. Ascites is most commonly seen in cockatiels and waterfowl.<sup>3,4</sup> Nesting behavior or recent egg laying is commonly reported at presentation.<sup>3</sup> Abdominal wall herniation may be a complication in cases of extreme abdominal distension secondary to increased coelomic pressure.<sup>5</sup>

Although ascites is not present in all birds with egg yolk peritonitis, fluid evaluation may be diagnostic when ascites is a presenting clinical sign. Grossly, the fluid is slightly yellow to yellow, with possible visualiza-

tion of yolk material and protein strands. The fluid may appear noninflammatory (as in this case) or inflammatory, with or without sepsis. Typical findings would be only yolk or fat globules in the former case and a mixture of heterophils, macrophages, lymphocytes, fat globules, and yolk globules with or without bacteria in the latter case.<sup>2,3</sup> Any ascitic fluid from a bird should be cultured, especially in cases of egg yolk peritonitis. Coliform bacteria have been the most common isolates in egg yolk peritonitis.<sup>6</sup>

In mammals, fluid effusions are typically assigned to the categories of transudate, modified transudate, and exudate for identification of the underlying etiology. In birds, this categorization may be more difficult to apply. The abdominal fluid in this bird had high total protein content (7.4 g/dL) and low cellularity (250 cells/ $\mu$ L). The high protein value may have been an artifact of the refractometry method, which in birds can produce a falsely elevated result compared with the biuret method.<sup>7</sup> The high total protein value also may be attributed to the lipid and protein content of the yolk itself. Yolk is composed of 33% lipid, 17% protein, 48% water, 0.2% free carbohydrate, and 1% inorganic elements.<sup>8</sup>

This case demonstrates an uncommon and interesting cytologic finding and shows how cytologic evaluation of abdominal effusion in birds can be a valuable tool in the diagnosis of egg yolk peritonitis. Because egg yolk peritonitis may lack an inflammatory component, peritonitis may be an inappropriate term.  $\diamond$

**Key Words:** Avian, cockatiel, egg yolk peritonitis

**Citation:** Caruso KJ, Cowell RL, Meinkoth JH, Klaassen JK. Abdominal effusion in a bird [egg yolk peritonitis]. *Vet Clin Pathol.* 2002;31:127-128.

© 2002 American Society for Veterinary Clinical Pathology

### References

1. Roskopf WJ, Woerpel RW. Avian obstetrical medicine. *Proc Assoc Avian Vet.* Lake City, Fla: Assoc Avian Vet Publications; 1993:328.
2. Roskopf WJ, Woerpel RW. *Diseases of Cage and Aviary Birds.* 3rd ed. Baltimore, Md: Williams and Wilkins; 1996:694.
3. Altman RB, Clubb SL, Dorrestein GM, Quesenberry K. Noninfectious diseases. In: Altman RB, ed. *Avian Medicine and Surgery.* Philadelphia, Pa: WB Saunders Co; 1997:636.
4. Ritchie BW, Harrison GJ. Supportive care and emergency therapy. In: Harrison LR, ed. *Avian Medicine: Principles and Application.* Lake Worth, Fla: Wingers Publishing, Inc; 1994:408.
5. Powers LV, Degernes LA, Starrak G, Douglass J, Cornish T. What is your diagnosis? *J Avian Med Surg.* 1996;10:126-129.
6. Harcourt-Brown NH. Torsion and displacement of the oviduct as a cause of egg-binding in four psittacine birds. *J Avian Med Surg.* 1996;10:262-267.
7. Lumeij JT. Avian clinical biochemistry. In: Kaneko JJ, Harvey JW, Bruss ML eds. *Clinical Biochemistry of Domestic Animals.* 5th ed. San Diego, Calif: Academic Press; 1997:860-861.
8. Johnson AL. Reproduction in the female. In: Whittow GC, ed. *Sturkie's Avian Physiology.* 5th ed. San Diego, Calif: Academic Press; 1995:586.